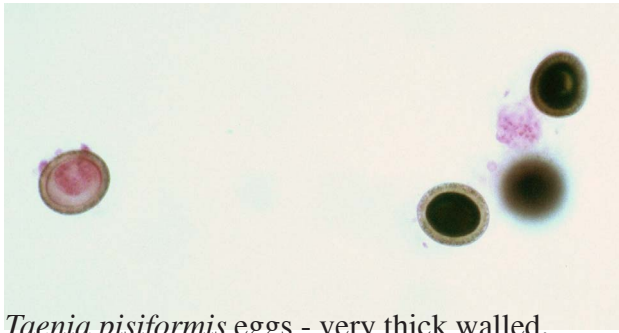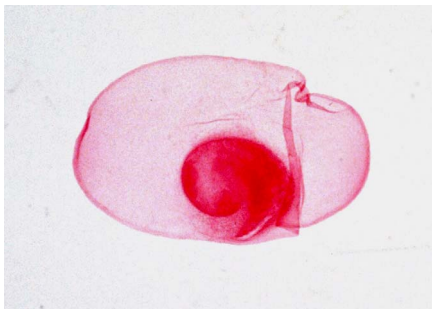


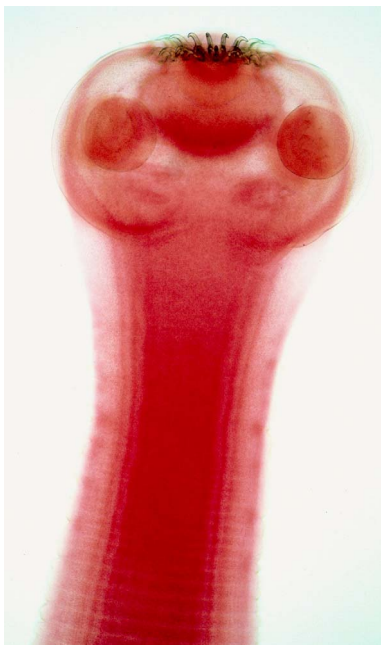Cestode tapeworms - 1



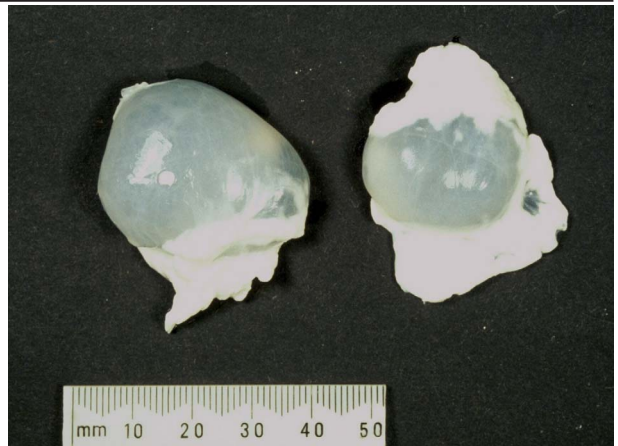Taenia pisiformis eggs - very thick walled.



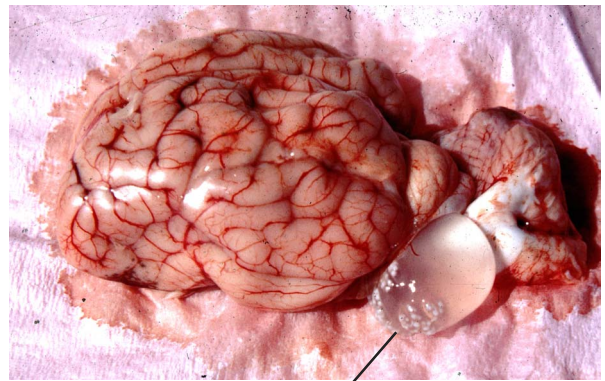
Taenia saginata larval cysts from cattle muscle. Cysticercus type of cyst.



Taenia pisiformis adult scolex, showing ring of hooks and four suckers for attachment to intestine of dog.



Taenia hydatigena larval cysts from cattle abdominal mesentery. Cysticercus type of cyst.



Taenia multiceps larval cyst in brain of sheep. Coenurus type of cyst.



Taenia pisiformis adult tapeworm from intestine of dog final host. A medium sized tapeworm.